



**PATIENT**

Schall Coughlin

**SPECIES**

Canine

**BREED**

Golden Retriever

**SEX**

Female Spayed

**AGE**

5 years

**WEIGHT**

51.6lbs

**INTERPRETED BY**

Maggie Machen Lamy,  
DVM, DACVIM  
(Cardiology)

**IMAGING PERFORMED BY**

Sands Hill Mobile  
Veterinary Ultrasound

**HOSPITAL NAME**

Surf City Animal  
Hospital

**REFERRING VET**

Dr. Tarter

**INVOICE**

26660

**DATE**

10/3/22

**PRESENTING CLINICAL SIGNS**

History: Recheck echo. Doing well.

-Pertinent previous echo (3/2022 KB): Previously diagnosed with suspect DCM due to a grain-free diet. LVIDd: 5.06, LVIDs: 4.07, FS: 19.6%, LA: 4.3. A diet change, Taurine supplementation, Pimobendan and Enalapril were recommended.

**ECHOCARDIOGRAM FINDINGS**

2D, m-mode, color flow and doppler imaging is available. The mitral valve is normal with no mild prolapse into the left atrial lumen. Trace eccentric MR with no left atrial dilation. Mild LV dilation in diastole with moderate dilation in systole (LVIDdN: 1.87, LVIDsN: 1.4). Moderate decline in myocardial function. Normal LV wall thickness. Increased LV sphericity. The tricuspid valve appears normal in form and function. Mild TR with normal velocity. Prominent right atrial and ventricular diameter. No overt evidence of pulmonary arterial hypertension or right heart decompensation. The aortic valve is normal in morphology and mobility. No subvalvular ridge present; normal LVOT velocity with laminar flow. Normal RVOT velocity with laminar flow. No pericardial or pleural effusion noted. No obvious cardiac tumors.

**CARDIAC CHART**

CANINE CARDIAC PARAMETERS	MR VMAX (m/s)	TR VMAX (m/s)	LA/AO (Boon method)	LA/AO (Heart Base; Swe)	FS (%)	EF (%)	EPSS (cm)
NORMAL PARAMETER	4.5-5.5	<2.7	1.3	<1.6	28-40	40-100	<0.6
PATIENT	NM	2.7	1.8	1.2	20	36	0.73
CANINE CARDIAC PARAMETERS	HR (BPM)	AV VMAX (m/s)	PV MAX (m/s)	BODY WEIGHT (kg)	LA 2D short axis Base view (cm)	LVIDd Avg: 2D and m-mode short axis (cm)	LVIDs Avg: 2D and m-mode short axis (cm)
NORMAL PARAMETER	50-100	0.7-1.7	0.7-1.6	BELOW	BELOW	BELOW	BELOW
PATIENT	88	1.0	0.9	23.4	2.4	4.7	3.8
*Normal chamber parameters expressed as a mean value (SD)				3	1.27 (5.3)	2.46 (2.46)	1.36 (5.5)
<b>BODY WEIGHT DEPENDENT PARAMETERS</b>				5	1.40 (4.5)	2.74 (5.2)	1.60 (4.7)
<i>*Note: All measurements based upon multi-modal images and methods. An average value is reported.</i>				10	1.50 (3.8)	3.27 (3.5)	2.06 (3.1)
				15	1.83 (2.0)	3.71 (2.4)	2.43 (2.1)
				20	2.02 (1.9)	4.14 (2.2)	2.80 (2.0)
				25	2.18 (2.4)	4.48 (2.9)	3.10 (2.5)
				30	2.33 (3.3)	4.83 (3.9)	3.39 (3.4)
				35	2.48 (4.3)	5.17 (5.0)	3.69 (4.5)
				40	2.62 (5.2)	5.48 (6.1)	3.96 (5.4)
				50	2.88 (7.1)	6.07 (8.3)	4.46 (7.4)

**INTERPRETATION OF THE FINDINGS & FURTHER RECOMMENDATIONS**

Compared to the prior study, the LV dilation has improved slightly. The diastolic dimension remains mildly increased and the fractional shortening is similar to previous. The LA remains normal, indicating low risk for complication. Taken in total, these findings likely reflect relative stability without a dramatic improvement following the diet change. No obvious additional issues are identified.



**PATIENT**

Schall Coughlin

Given these findings, continue Pimobendan and Enalapril as previously recommended in addition to the taurine supplement. No additional medications are indicated.

**SPECIES**

Canine

Prognosis remains guarded long-term however it is encouraging that the patient remains asymptomatic. There may be risk for development of congestive heart failure, malignant arrhythmias (AF, VT), collapse and/or sudden death in the future.

**BREED**

Golden Retriever

Monitor for development of a murmur, cough, labored breathing, exercise intolerance or collapse episodes.

**SEX**

Female Spayed

**PLAN**

Continue Pimobendan 0.3mg/kg PO q12h. Continue ACE-I 0.5mg/kg PO q12h with periodic blood pressure monitoring. Continue Taurine supplement lifelong.

**AGE**

5 years

A recheck echocardiogram is recommended in 6 months, sooner if a murmur develops or any signs of cardiac disease are noted.

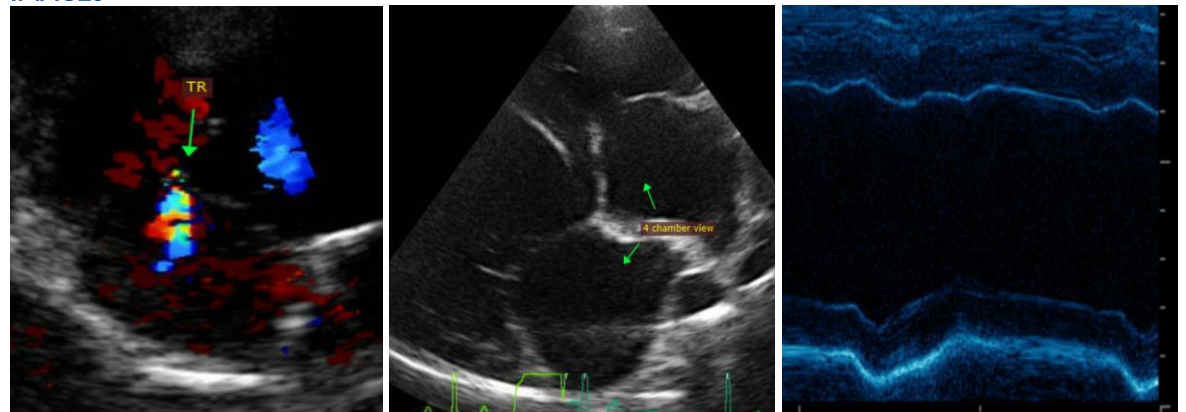
**WEIGHT**

51.6lbs

**IMAGES**

**INTERPRETED BY**

Maggie Machen Lamy,  
DVM, DACVIM  
(Cardiology)



**IMAGING PERFORMED BY**

Sands Hill Mobile  
Veterinary Ultrasound

The information and recommendations provided are based on the images presented by the referring veterinarian. No evaluation can be communicated regarding pathology that was not visible in the image/video clips provided.

**HOSPITAL NAME**

Surf City Animal  
Hospital

Thank you for this referral. This report was generated using transcription software, and minor dictation errors may be present. If the clinical or image interpretation does not parallel your findings or if I can be of any further assistance, please contact me.

**REFERRING VET**

Dr. Tarter

Maggie Machen Lamy, DVM  
Diplomate of the American College of Veterinary Internal Medicine (Cardiology)  
info@sonopath.com

**INVOICE**

26660

**DATE**

10/3/22